

学位論文

Intratumoral heterogeneity of ^{18}F -FLT uptake predicts proliferation
and survival in patients with newly diagnosed glioma

香川大学大学院医学系研究科
社会環境病態学

三田村 克哉



ORIGINAL ARTICLE

Intratumoral heterogeneity of ^{18}F -FLT uptake predicts proliferation and survival in patients with newly diagnosed gliomas

Katsuya Mitamura¹ · Yuka Yamamoto¹ · Nobuyuki Kudomi² · Yukito Maeda³ · Takashi Norikane¹ · Keisuke Miyake⁴ · Yoshihiro Nishiyama¹

Received: 23 June 2016 / Accepted: 23 September 2016
© The Japanese Society of Nuclear Medicine 2016

Abstract

Background The nucleoside analog 3'-deoxy-3'- ^{18}F -fluorothymidine (FLT) has been investigated for evaluating tumor proliferating activity in brain tumors. We evaluated FLT uptake heterogeneity using textural features from the histogram analysis in patients with newly diagnosed gliomas and examined correlation of the results with proliferative activity and patient prognosis, in comparison with the conventional PET parameters.

Methods FLT PET was investigated in 37 patients with newly diagnosed gliomas. The conventional parameters [tumor-to-contralateral normal brain tissue (T/N) ratio and metabolic tumor volume (MTV)] and textural parameters (standard deviation, skewness, kurtosis, entropy, and uniformity) were derived from FLT PET images. Linear regression analysis was used to compare PET parameters and the proliferative activity as indicated by the Ki-67 index. The associations between parameters and overall survival (OS) were tested by Cox regression analysis.

Results Median OS was 662 days. For the conventional parameters, linear regression analysis indicated a significant correlation between T/N ratio and Ki-67 index

($p = 0.02$) and MTV and Ki-67 index ($p = 0.02$). Among textural parameters, linear regression analysis indicated a significant correlation for kurtosis ($p = 0.003$), entropy ($p < 0.001$), and uniformity ($p < 0.001$) as compared to Ki-67 index, exceeding those of the conventional parameters. The results of univariate analysis suggested that skewness and kurtosis were associated with OS ($p = 0.03$ and 0.02 , respectively). Mean survival for patients with skewness values less than 0.65 was 1462 days, compared with 917 days for those with values greater than 0.65 ($p = 0.02$). Mean survival for patients with kurtosis values less than 6.16 was 1616 days, compared with 882 days for those with values greater than 6.16 ($p = 0.006$).

Conclusions Based on the results of this preliminary study in a small patient population, textural features reflecting heterogeneity on FLT PET images seem to be useful for the assessment of proliferation and for the potential prediction of survival in newly diagnosed gliomas.

Keywords ^{18}F -FLT · PET · Glioma · Heterogeneity · Texture

Introduction

Tumors are heterogeneous on histopathological level with intratumoral spatial variation in cellularity, proliferation, hypoxia, angiogenesis, necrosis, and extracellular matrix [1]. A high level of intratumoral heterogeneity has been shown to have a high metastatic potential, a poor patient outcome, and poor response to treatment, although the biological relationship is still poorly understood [1–4]. It is difficult to assess intratumoral heterogeneity with tissue sampling which is not representative of the entire tumor.

✉ Yuka Yamamoto
yuka@kms.ac.jp

¹ Department of Radiology, Faculty of Medicine, Kagawa University, 1750-1 Ikenobe, Miki-cho, Kita-gun, Kagawa 761-0793, Japan

² Department of Medical Physics, Faculty of Medicine, Kagawa University, Kita-gun, Kagawa, Japan

³ Department of Clinical Radiology, Kagawa University Hospital, Kita-gun, Kagawa, Japan

⁴ Department of Neurosurgery, Faculty of Medicine, Kagawa University, Kita-gun, Kagawa, Japan

Textural features to assess tumor heterogeneity by anatomical imaging methods, including CT and MRI, have shown the ability to characterize tissues as well as predict treatment response and survival in some tumor types [5, 6]. Recent studies of textural analysis by functional imaging, including 2-deoxy-2-¹⁸F-fluoro-D-glucose (FDG) positron emission tomography (PET), have shown similar properties, although the biological mechanisms are unknown [7–11]. The most commonly used parameters for semi-quantitative analysis of PET images are the standardized uptake value (SUV) derived indices. In brain PET studies, the tumor-to-contralateral normal brain tissue (T/N) ratio, which is determined by dividing maximum SUV of the tumor by mean SUV of the reference tissue, is most commonly used for semiquantification. Colavolpe et al. demonstrated that T/N ratio on pretreatment FDG PET provided a significant additional prognostic information in newly diagnosed high-grade gliomas [12]. However, another study showed that FDG T/N ratio was not a significant prognostic factor for survival in glioma patients [13]. Beyond the relatively simple measurements of the level of tumor uptake, there is recently increasing recognition that the measurement of intratumoral heterogeneity on FDG PET images can improve the prediction of prognostic value in several types of tumor [7–11].

Although FDG PET directly reflects the glucose metabolic activity of tumor cells and is predictive of patient outcome [12], the utility of FDG PET for assessing brain tumor is limited due to high normal brain uptake of FDG. Another radiotracer, 3'-deoxy-3'-¹⁸F-fluorothymidine (FLT) has been investigated as a promising PET tracer for evaluating tumor proliferating activity in brain tumors [14–20]. Unlike FDG, FLT does not have high background activity in normal gray matter structures. It is trapped within the cytosol after being monophosphorylated by thymidine kinase-1 (TK1), a principle enzyme in the salvage pathway of DNA synthesis [21]. Therefore, the accumulation of FLT is dependent on the presence of TK1, which is closely associated with cellular proliferation. In brain gliomas, FLT has been validated for the evaluation of cellular proliferation [14–16]. Furthermore, FLT PET was found to be a more significant predictor of the overall survival (OS) than contrast-enhanced MRI alone in malignant glioma patients [18].

There is still limited experience of the PET textural analysis in patients with brain gliomas [22]. That study [22] used ¹⁸F-fluoroethyl-L-tyrosine (FET) PET, but there has been no report of use of FLT. The purpose of the present study was to retrospectively evaluate FLT uptake heterogeneity in patients with newly diagnosed gliomas using textural features from histogram analysis and to correlate the results with proliferative activity as indicated by the Ki-67 index and patient prognosis, in comparison with the

conventional PET parameters, T/N ratio, and metabolic tumor volume (MTV).

Methods

Patients

This study was approved by our institutional ethical review committee, and written informed consent was obtained from all patients.

From August 2010 to March 2016, 41 patients with newly diagnosed gliomas underwent FLT PET/CT. Of these, 4 patients were excluded, because they did not exhibit sufficient FLT uptake in the tumor to perform volumetric and textural analysis. As a result, 37 patients (15 males, 22 females; mean age, 55.8 years; age range, 8–84 years) were included in the study.

Pathologic diagnosis had been obtained by stereotactic biopsy or open surgery. The distribution of tumor grade and type according to World Health Organization classification [23] was as follows: 4 grade II diffuse astrocytomas, 9 grade III anaplastic astrocytomas, 2 grade III anaplastic oligodendrogliomas, 1 grade III anaplastic ependymoma, and 21 grade IV glioblastomas.

FLT synthesis and PET/CT imaging

FLT was synthesized using the method described by Machulla et al. [24].

All acquisitions were performed using a Biograph mCT 64-slice PET/CT scanner (Siemens Medical Solutions USA Inc., Knoxville, TN, USA). Data acquisition began with CT at the following settings: no contrast agent, 120 kV, 192 mA, 1.0-s tube rotation time, 3-mm slice thickness, 3-mm increments, and pitch 0.55. PET emission scanning of the head region with a 15-min acquisition of one bed position was performed 60 min after intravenous injection of FLT (3.7 MBq/kg). The PET data were acquired in three-dimensional mode and were reconstructed by the baseline-ordered-subset expectation maximization bases, incorporating correction with point spread function and time-of-flight model (5 iterations and 21 subsets). A Gaussian filter with a full-width at half-maximum of 3 mm was used as a post-smoothing filter.

Image analyses

An experienced nuclear medicine physician, who was blinded to the patient outcome, performed the image analyses. Volumes of interest (VOIs) of the tumor on FLT PET images were selected using a threshold of 40 % of the maximum SUV. If nontumoral areas of activity were

incorrectly included within the VOI, adjustments were performed by the operator.

First-order textural features included the standard deviation of the gray-level histogram distribution, skewness (asymmetry of the histogram), kurtosis (flatness of the histogram), entropy (irregularity of gray-level distribution), and uniformity (uniformity of gray-level distribution) [25–27] (Fig. 1). Calculation of the textural features was performed using the in-house software in C environment (gcc 4.9.3). Those features were obtained by applying pixel positions and their values extracted from the selected VOIs. For the reference tissue, a circular region of interest of 10×10 mm was manually placed on the uninvolved contralateral hemisphere on the plane that showed maximum tumor uptake. The T/N ratio and MTV as the conventional PET parameters were derived from the same VOIs.

Ki-67 immunohistochemistry

Formalin-fixed, paraffin-embedded sections of resected specimens from brain tumor were made for immunohistochemical staining. The Ki-67 index was estimated as the percentage of Ki-67-positive cell nuclei per 500–1000 cells in the region of the tumor with the greatest density of staining.

Statistical analysis

All statistical analyses were performed using a software package (SPSS Statistics, version 22; IBM). Correlations between the Ki-67 index and all PET parameters were examined using linear regression analysis. Associations between the conventional and textural parameters were also investigated using linear regression analysis. OS or time to last censoring was calculated from the date of PET examination to death or the date of the last follow-up. The threshold value that was most discriminating in terms of

differentiating between two groups of patients was selected using receiver operating characteristic methodology. The separate association between each parameter and OS was assessed by univariate Cox regression analysis, because the number of events did not allow a multivariate analysis. Kaplan–Meier curves were calculated for parameters that showed statistical significance after univariate analysis, and differences were assessed using a log-rank test. Differences were considered statistically significant at a p value of less than 0.05.

Results

All measured PET parameters, namely, T/N ratio, MTV (ml), standard deviation, skewness, kurtosis, entropy, and uniformity are summarized in Table 1.

Association with Ki-67 immunohistochemistry

Data on the Ki-67 immunohistochemical staining were available for 34 out of 37 patients. For the conventional parameters, linear regression analysis indicated a significant correlation between T/N ratio ($r = 0.39, p = 0.02$) and MTV ($r = 0.40, p = 0.02$), and Ki-67 index. Among textural parameters, linear regression analysis indicated a significant correlation for kurtosis ($r = 0.49, p = 0.003$), entropy ($r = 0.73, p < 0.001$), and uniformity ($r = -0.62, p < 0.001$) as compared to Ki-67 index, exceeding those of the conventional parameters. There was no significant correlation for the standard deviation ($r = 0.29, p = 0.10$) and skewness ($r = 0.24, p = 0.18$), compared to the Ki-67 index.

Association between the conventional and textural parameters

In all patients, significant correlations were seen for T/N ratio compared with the standard deviation ($r = 0.75$,

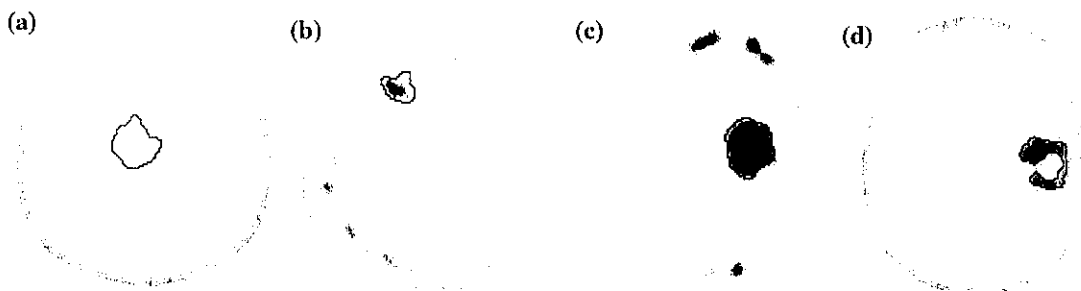


Fig. 1 FLT PET images of examples of four gliomas. **a** Grade II diffuse astrocytoma with low textural skewness (-0.27) and low textural kurtosis (3.94), **b** grade III anaplastic astrocytoma with high textural skewness (0.80) and low textural kurtosis (5.97), **c** grade IV

glioblastoma high textural skewness (0.72) and low textural kurtosis (4.93), and **d** grade IV glioblastoma with high textural skewness (1.44) and high textural kurtosis (11.87)

Table 1 All parameters measured on FLT PET for 37 patients with newly diagnosed gliomas

FLT PET parameter	Median	Range
T/N ratio	10.64	1.82 to 35.92
MTV (ml)	37.36	1.06 to 105.54
Standard deviation	0.84	0.17 to 2.90
Skewness	0.47	-0.41 to 1.91
Kurtosis	5.97	3.71 to 11.87
Entropy	2.50	2.00 to 3.09
Uniformity	0.21	0.13 to 0.27

Table 2 Results of univariate analysis of clinical and FLT PET parameters and their association with the overall survival in 37 patients with newly diagnosed gliomas

Parameter	Overall survival	
	<i>p</i>	Hazard ratio
Sex	0.22	0.51 (0.17, 1.48)
Age	0.32	1.01 (0.98, 1.04)
WHO grade	0.37	2.56 (0.33, 19.92)
T/N ratio	0.13	2.59 (0.75, 8.88)
MTV (ml)	0.36	0.49 (0.11, 2.20)
Standard deviation	0.12	2.46 (0.80, 7.60)
Skewness	0.03	3.71 (1.21, 11.38)
Kurtosis	0.02	5.14 (1.41, 18.72)
Entropy	0.21	1.98 (0.68, 5.76)
Uniformity	0.40	0.63 (0.21, 1.82)

Data in parentheses are 95 % CIs

T/N ratio tumor-to-contralateral normal brain tissue ratio, MTV metabolic tumor volume

$p < 0.001$), skewness ($r = 0.47$, $p = 0.004$), and kurtosis ($r = 0.37$, $p = 0.03$). A significant correlation was also found between MTV and entropy ($r = 0.38$, $p = 0.03$).

Association with OS

Data on OS were also available for all patients. Median OS was 662 days, with 23 survivors at the time of analysis.

In univariate analysis, skewness ($p = 0.03$) and kurtosis ($p = 0.02$) were significantly associated with survival (Table 2). Standard deviation, entropy, and uniformity as well as the conventional parameters, T/N ratio and MTV, yielded no significant results on OS analysis (Table 2).

Mean survival for patients with skewness values less than 0.65 was 1462 days, compared with 917 days for those with values greater than 0.65 ($p = 0.02$) (Fig. 2a). Mean survival for patients with kurtosis values less than 6.16 was 1616 days, compared with 882 days for those with values greater than 6.16 ($p = 0.006$) (Fig. 2b).

Discussion

In the present study, we evaluated FLT uptake heterogeneity using textural features from histogram analysis in patients with newly diagnosed gliomas. Textural and conventional parameters on FLT PET images were found to be useful in the assessment of tumor proliferation. Moreover, the correlation coefficient for textural parameters was higher than that for the conventional parameters. In univariate analysis, skewness and kurtosis were associated with OS.

Currently, in brain PET studies, SUV-based parameters, such as maximum SUV and T/N ratio, are used most frequently and are considered to be related to several clinicopathological factors in brain tumors [12–20]. However, an important disadvantage associated with these parameters is that they do not essentially reflect the total activity for the whole tumor. A noninvasive method of assessing the intratumoral heterogeneity might be a valuable clinical tool in oncologic imaging, because tumors exhibit heterogeneity. In medical imaging, tumor heterogeneity can be assessed by several texture-based methods. To the best of our knowledge, there appears to be still limited experience of evaluating PET textural analysis in patients with brain gliomas [22]. That study [22] was done using FET PET [22]. The present study is the first report to examine FLT PET uptake heterogeneity in patients with newly diagnosed gliomas, in comparison with conventional PET parameters.

Increased cell proliferation and DNA replication is a characteristic of malignant transformation [28]. The assessment of cellular proliferation rate by means of PET is useful as a noninvasive clinical approach. Actually, uptake of FLT has previously been described as a useful predictive parameter of cell proliferation in various types of tumors, including gliomas [29]. Choi et al. showed a significant correlation between FLT T/N ratio and Ki-67 index in patients with gliomas [16]. The present study also showed a correlation between T/N ratio and MTV and Ki-67 index in newly diagnosed gliomas. Moreover, a correlation was also observed between textural parameters (kurtosis, entropy, and uniformity) and Ki-67 index, and the correlation coefficient for these textural parameters was higher than that for the conventional parameters. There are currently no reports comparing PET textural analysis and tumor proliferation in patients with brain gliomas. The heterogeneity of tracer uptake within tumors has been attributed to a number of factors, including not only cellular proliferation, but also cellularity, angiogenesis, necrosis, and vascularization [27]. Further studies are needed to evaluate the correlation between PET textural features and tumor proliferation in patients with the variety of tumor types.

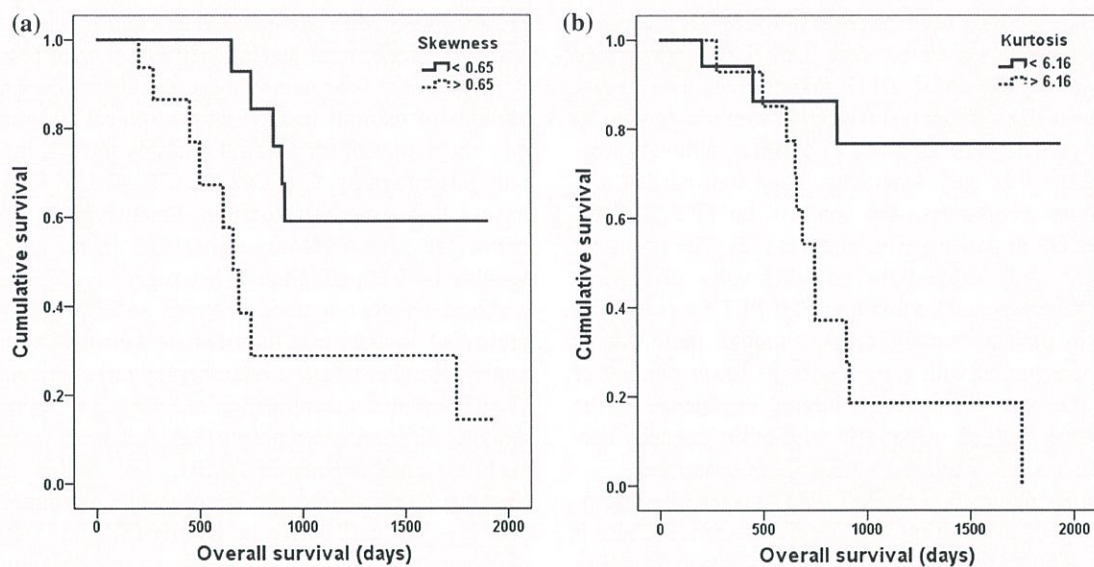


Fig. 2 Kaplan–Meier survival curves showing significantly different overall survivals for patients with **a** skewness values less than 0.65 (solid line) and those with skewness values greater than 0.65 (dotted

line) ($p = 0.02$) and **b** kurtosis values less than 6.16 (solid line) and those with kurtosis values greater than 6.16 (dotted line) ($p = 0.006$)

Changes in the conventional FLT PET parameters during treatment were reported to be predictive of OS in recurrent gliomas patients [20]. Zhao et al. indicated that T/N ratio and MTV derived from a pretreatment FLT PET were independent predictors of survival in patients with recurrent malignant gliomas [19]. However, these indices were not predictive of patient survival in the present study. One possible reason for this may be due to the clinical differences between the patient populations evaluated in the two studies. All our patients had newly diagnosed gliomas, including both high-grade and low-grade gliomas. On the other hand, all patients in the study by Zhao et al. [19] had recurrent high-grade gliomas. To date, studies on the clinical significance of intratumoral heterogeneity using PET textural analysis are limited, even though intratumoral heterogeneity is a potential prognostic factor. In non-small cell lung cancer (NSCLC), heterogeneity features on FDG PET have shown associations with response and survival after chemoradiotherapy [8, 9]. In cervical cancer, more heterogeneous distributions of FDG PET were related to greater risk of lymph node metastases, risk of local recurrence, and worse progression-free survival (PFS) [11]. Unfortunately, many of these studies are retrospective, performed in small number of patients. Moreover, they use a univariate approach and do not actually assess the incremental value of textural metrics over the conventional indices, such as SUV and MTV. Eary et al. evaluated 234 patients with sarcoma for tumor heterogeneity on baseline FDG PET and concluded that heterogeneity was a strong independent predictor of survival, and that maximum SUV was somewhat less predictive [10]. Cook et al. investigated

the prognostic value of baseline FDG PET heterogeneity in NSCLC [8]. They found that textural features performed better than SUV parameters and MTV, showing no significant association with outcome [8]. The present study also evaluated both textural and conventional parameters, and our findings are in line with results of Cook et al. [8] and Eary et al. [10]. Pyka et al. evaluated textural analysis using FET PET in patients with high-grade gliomas for assessing patient prognosis compared to T/N ratio and MTV [22]. Their results showed a significant correlation of FET PET texture but not T/N ratio with patient PFS and OS, on multivariate analysis [22]. Our findings in univariate analysis are also in line with their results [22]. Taken together, these results add to the growing body of evidence that the heterogeneity of tumor metabolism, measured by PET textural analysis, is an important prognostic factor, as it has already been demonstrated for glucose metabolism on FDG PET images of other tumor entities [7–11]. However, T/N ratio was not significantly related to OS in our and Pyka et al.'s studies [22]. In the present study, we have noted correlations between a number of textural features and T/N ratio, even though T/N ratio and heterogeneity parameters measure different characteristics. In our study, higher standard deviation, skewness, and kurtosis were more likely in tumors with high T/N ratio than in those with low T/N ratio. However, the relationship between these parameters and clinicopathological factors of brain tumors is diverse and has not been entirely elucidated. In Pyka et al.'s study, the correlation of WHO grade to OS was determined as significant in univariate analysis but not in multivariate analysis [22].

In univariate analysis of the present study, WHO grade was not significantly associated with OS. They categorized patients between grade III and IV gliomas [22]. The present study categorized patients between low-grade (grade II) and high-grade (grade III and IV) gliomas, although low-grade glioma was only 4 patients. They showed that textural feature, coarseness, and contrast, on FET PET for predicting OS in patients with gliomas [22]. The results of the present study suggest the potential value of textural feature, skewness, and kurtosis, on FLT PET for predicting survival in patients with gliomas, although these details must be interpreted with care due to the lower number of patients. To date, there is still limited experience of the PET textural analysis in patients with brain gliomas. Further larger patient populations need to be examined.

For tumor delineation on FLT PET images, the threshold of 40 % of the maximum SUV was chosen, because it provides a good tradeoff allowing for appropriate delineation of the tumor against normal tissue without the loss of too many voxels. Tumor delineation on PET images is less than straightforward. Many delineation methods exist, such as manual contouring, value thresholding, percentage thresholding, and a variety of other semiautomated techniques. Van de Wiele et al. mentioned that the optimal threshold for tumor delineation was shown to be inversely related to tumor size and maximum SUV [30]. In the present study, some of tumors were too small activity volume and too low SUV. It is not possible to exclude an effect from tumor size and tumor uptake. Brooks and Grigsby suggested that the inclusion of tumor volumes below 45 ml could bias comparisons of intratumoral uptake heterogeneity metrics derived from data from the current generation of PET scanners [31]. It may be necessary to define a minimum tumor volume and minimum tumor uptake for textural analysis.

In the present study, PET images were reconstructed by the baseline-ordered-subset expectation maximization bases, incorporating correction with point spread function and time-of-flight model. The impact of reconstruction settings on textural features is not yet clear, especially relating to point spread function and time-of-flight model. There is a need to re-evaluate the robustness of textural features with respect to acquisition mode and reconstruction parameters.

Limitations of the present study include small sample size and retrospective design. The number of events and patients did not allow a multivariate analysis. Moreover, the intratumoral heterogeneity can be represented by various methods. For example, first-order features only consider the statistical distribution of the intensity of each pixel, while second-order features consider the relation of two pixels adjacent to each other. In the present study, only the first-order features were analyzed. Additional large

prospective studies are needed to confirm the predictive value of intratumoral heterogeneity in clinical practice.

While there is accumulating literature on the predictive abilities of textural features in anatomical imaging methods, the evidence for textural analysis in PET imaging is only just emerging. Compared to CT or MRI, PET images have a lower spatial resolution. Small tumors, which are below the spatial resolution of PET scans, may not be suitable for evaluating tumor heterogeneity. Yu et al. have assessed whether textural features in FDG PET/CT co-registered images can differentiate between normal and abnormal nodes to assist radiotherapy target planning [32]. They found that a combination of PET and CT textures had a higher discriminative power [32]. Advances in hardware, such as simultaneous PET/MRI, will further stimulate imaging research into the analysis of intratumor heterogeneity. Textural analysis maximizes the information obtained from the standard clinical images without the need for additional acquisitions. To date, there have been few tumor heterogeneity studies using newer radiopharmaceuticals other than FDG. Further studies are needed to investigate textural features using different imaging modalities and different PET tracers to elucidate their potential clinical value.

Conclusion

Based on the results of this preliminary study in a small patient population, textural features reflecting heterogeneity on FLT PET images seem to be useful for the assessment of tumor proliferation and for potential prediction of survival, in patients with newly diagnosed gliomas.

Compliance with ethical standards

Conflict of interest No potential conflict of interest relevant to this article was reported.

References

1. Davnall F, Yip CS, Ljungqvist G, Selmi M, Ng F, Sanghera B, et al. Assessment of tumor heterogeneity: an emerging imaging tool for clinical practice? *Insights Imaging*. 2012;3:573–89.
2. Höckel M, Knoop C, Schlenger K, Vorndran B, Baussmann E, Mitze M, et al. Intratumoral pO₂ predicts survival in advanced cancer of the uterine cervix. *Radiother Oncol*. 1993;26:45–50.
3. Yang Z, Tang LH, Klimstra DS. Effect of tumor heterogeneity on the assessment of Ki67 labeling index in well-differentiated neuroendocrine tumors metastatic to the liver: implications for prognostic stratification. *Am J Surg Pathol*. 2011;35:853–60.
4. Höckel M, Schlenger K, Aral B, Mitze M, Schaffer U, Vaupel P. Association between tumor hypoxia and malignant progression in advanced cancer of the uterine cervix. *Cancer Res*. 1996;56:4509–15.

5. Goh V, Ganeshan B, Nathan P, Juttla JK, Vinayan A, Miles KA. Assessment of response to tyrosine kinase inhibitors in metastatic renal cell cancer: CT texture as a predictive biomarker. *Radiology*. 2011;261:165–71.
6. Ganeshan B, Skogen K, Pressney I, Coutroubis D, Miles K. Tumour heterogeneity in oesophageal cancer assessed by CT texture analysis: preliminary evidence of an association with tumour metabolism, stage, and survival. *Clin Radiol*. 2012;67:157–64.
7. Tixier F, Le Rest CC, Hatt M, Albarghach N, Pradier O, Metges JP, et al. Intratumor heterogeneity characterized by textural features on baseline ¹⁸F-FDG PET images predicts response to concomitant radiochemotherapy in esophageal cancer. *J Nucl Med*. 2011;52:369–78.
8. Cook GJ, Yip C, Siddique M, Goh V, Chicklore S, Roy A, et al. Are pretreatment ¹⁸F-FDG PET tumor textural features in non-small cell lung cancer associated with response and survival after chemoradiotherapy? *J Nucl Med*. 2013;54:19–26.
9. Tixier F, Hatt M, Valla C, Fleury V, Lamour C, Ezzouhri S, et al. Visual versus quantitative assessment of intratumor ¹⁸F-FDG PET uptake heterogeneity: prognostic value in non-small cell lung cancer. *J Nucl Med*. 2014;55:1235–41.
10. Eary JF, O'Sullivan F, O'Sullivan J, Conrad EU. Spatial heterogeneity in sarcoma ¹⁸F-FDG uptake as a predictor of patient outcome. *J Nucl Med*. 2008;49:1973–9.
11. Kidd EA, Grigsby PW. Intratumoral metabolic heterogeneity of cervical cancer. *Clin Cancer Res*. 2008;14:5236–41.
12. Colavolpe C, Metellus P, Mancini J, Barrie M, Béquet-Boucard C, Figarella-Branger D, et al. Independent prognostic value of pre-treatment ¹⁸F-FDG-PET in high-grade gliomas. *J Neurooncol*. 2012;107:527–35.
13. Kim S, Chung JK, Im SH, Jeong JM, Lee DS, Kim DG, et al. ¹¹C-methionine PET as a prognostic marker in patients with glioma: comparison with ¹⁸F-FDG PET. *Eur J Nucl Med Mol Imaging*. 2005;32:52–9.
14. Hatakeyama T, Kawai N, Nishiyama Y, Yamamoto Y, Sasakawa Y, Ichikawa T, et al. ¹¹C-methionine (MET) and ¹⁸F-fluorothymidine (FLT) PET in patients with newly diagnosed glioma. *Eur J Nucl Med Mol Imaging*. 2008;35:2009–17.
15. Chen W, Cloughesy T, Kamdar N, Satyamurthy N, Bergsneider M, Liau L, et al. Imaging proliferation in brain tumors with ¹⁸F-FLT PET: comparison with ¹⁸F-FDG. *J Nucl Med*. 2005;46:945–52.
16. Choi SJ, Kim JS, Kim JH, Oh SJ, Lee JG, Kim CJ, et al. [¹⁸F]3'-deoxy-3'-fluorothymidine PET for the diagnosis and grading of brain tumors. *Eur J Nucl Med Mol Imaging*. 2005;32:653–9.
17. Spence AM, Muzi M, Link JM, O'Sullivan F, Eary JF, Hoffman JM, et al. NCI-sponsored trial for evaluation of safety and preliminary efficacy of 3'-Deoxy-3'-[F-18]fluorothymidine (FLT) as a marker of proliferation in patients with recurrent gliomas: preliminary efficacy studies. *Mol Imaging Biol*. 2009;11:343–55.
18. Chen W, Dalaloye S, Silverman DH, Geist C, Czernin J, Sayre J, et al. Predicting treatment response of malignant gliomas to bevacizumab and irinotecan by imaging proliferation with [¹⁸F]fluorothymidine positron emission tomography: a pilot study. *J Clin Oncol*. 2007;25:4714–21.
19. Zhao F, Cui Y, Li M, Fu Z, Chen Z, Kong L, et al. Prognostic value of 3'-deoxy-3'-¹⁸F-fluorothymidine ([¹⁸F] FLT PET) in patients with recurrent malignant gliomas. *Nucl Med Biol*. 2014;41:710–5.
20. Schwarzenberg J, Czernin J, Cloughesy TF, Ellingson BM, Pope WB, Geist C, et al. 3'-deoxy-3'-¹⁸F-fluorothymidine PET and MRI for early survival predictions in patients with recurrent malignant glioma treated with bevacizumab. *J Nucl Med*. 2012;53:29–36.
21. Rasey JS, Grierson JR, Wiens LW, Kolb PD, Schwartz JL. Validation of FLT uptake as a measure of thymidine kinase-1 activity in A549 carcinoma cells. *J Nucl Med*. 2002;43:1210–7.
22. Pyka T, Gempt J, Hiob D, Ringel F, Schlegel J, Bette S, et al. Textural analysis of pre-therapeutic [¹⁸F]-FET-PET and its correlation with tumor grade and patient survival in high-grade gliomas. *Eur J Nucl Med Mol Imaging*. 2016;43:133–41.
23. Louis DN, Ohgaki H, Wiestler OD, Cavenee WK, Burger PC, Jouvet A, et al. The 2007 WHO classification of tumours of the central nervous system. *Acta Neuropathol*. 2007;114:97–109.
24. Machulla HJ, Blocher A, Kuntzsch M, Piert M, Wei R, Grierson JR. Simplified labeling approach for synthesizing 3'-deoxy-3'-[¹⁸F]fluorothymidine ([¹⁸F]FLT). *J Radioanal Nucl Chem*. 2000;243:843–6.
25. Amadasun M, King R. Textural features corresponding to textural properties. *IEEE Trans Syst Man Cybern*. 1989;19:1264–74.
26. Radulescu E, Ganeshan B, Minati L, Beacher FDCC, Gray MA, Chatwin C, et al. Gray matter textural heterogeneity as a potential in vivo biomarker of fine structural abnormalities in Asperger syndrome. *Pharmacogenomics J*. 2013;13:70–9.
27. Chicklore S, Goh V, Siddique M, Roy A, Marsden PK, Cook GJ. Quantifying tumour heterogeneity in ¹⁸F-FDG PET/CT imaging by texture analysis. *Eur J Nucl Med Mol Imaging*. 2013;40:133–40.
28. la Fougère C, Suchorska B, Bartenstein P, Kreth FW, Tonn JC. Molecular imaging of gliomas with PET: opportunities and limitations. *Neuro Oncol*. 2011;13:806–19.
29. Barwick T, Bencherif B, Mountz JM, Avril N. Molecular PET and PET/CT imaging tumour cell proliferation using F-18 fluorothymidine: a comprehensive evaluation. *Nucl Med Commun*. 2009;30:908–17.
30. Van de Wiele C, Kruse V, Smeets P, Sathekge M, Maes A. Predictive and prognostic value of metabolic tumour volume and total lesion glycolysis in solid tumours. *Eur J Nucl Med Mol Imaging*. 2013;40:290–301.
31. Brooks FJ, Grigsby PW. The effect of small tumor volumes on studies of intratumoral heterogeneity of tracer uptake. *J Nucl Med*. 2014;55:37–42.
32. Yu H, Caldwell C, Mah K, Mozeg D. Coregistered FDG PET/CT-based textural characterization of head and neck cancer for radiation treatment planning. *IEEE Trans Med Imaging*. 2009;28:374–83.